

Optimization of the development of reproductive organs celepuk jawa (*otus angelinae*) owl which supplemented by turmeric powder

by Tyas Rini Saraswati

Submission date: 28-Jan-2020 03:18PM (UTC+0700)

Submission ID: 1247598588

File name: roductive_organ_celepuk_jawa_otus_angelinae_owl_which_suppl.pdf (291.11K)

Word count: 2714

Character count: 14470

PAPER • OPEN ACCESS

Optimization of the development of reproductive organs celepuk jawa (*otus angelinae*) owl which supplemented by turmeric powder

To cite this article: Tyas Rini Saraswati *et al* 2018 *IOP Conf. Ser.: Earth Environ. Sci.* **130** 012008

View the [article online](#) for updates and enhancements.

Related content

- [Organ Printing: Future work](#)
D-W Cho, J-S Lee, J Jang, J W Jung, J H Park and F Pati
- [Dimensionality and regional strike analyses of the Cibeber segment, Cimandiri fault zone, West Java, Indonesia](#)
F Febriani, L Handayani, A Setyani et al.
- [Late Miocene Molluscan Stage of Jawa Insight from New Field Studies](#)
Aswan, Elina Sufiati, Desty Kistiani et al.

Optimization of the development of reproductive organs celepuk jawa (*otus angelinae*) owl which supplemented by turmeric powder

Tyas Rini Saraswati^{1*}, Enny Yusuf W. Yuniwati¹, Silvana Tana¹

¹Biology Department, Faculty of Science and Mathematics, Diponegoro University, Semarang Indonesia.

*E-mail: tyasrinis63@gmail.com

Abstract. *Otus angelinae* is included as a protected animal because of its endangered existence. Whereas, it has many values such as for mice pest control. Therefore, this research aims to optimize the reproductive function of *Otus angelinae* by administering turmeric powder mixed in its feed. This study was held on a laboratory scale with two male and two female *Otus angelinae* three months of age. Each subject is divided into two groups: a control group and a treatment group which is treated with turmeric powder 108 mg/owl/day mixed in 30 g catfish/ day for a month. The parameter observed were the development of hierarchy follicles and the ovarium weight of female *Otus angelinae*, whereas the testis organs and testes weight were observed for the male. Both the female's and male's body weight, liver weight and the length of ductus reproduction were also observed. The data was analyzed descriptively. The results showed that the administration of turmeric powder can induce the development of ovarian follicles hierarchy and the length of ductus reproduction of female *Otus angelinae* and also induce the development of the testes and the length of ductus reproduction of male *Otus angelinae*. The addition of turmeric powder increased the liver weight of the female *Otus angelinae*, however it does not affect the body weight.

Keywords: follicle hierarchy, vittellogenin

1. Introduction

Owl is a bird of prey (carnivore) and a night animal (nocturnal). There are approximately 222 known species of owls, and they are spread around the world [1]. In Indonesia owl is a scarce and protected animal. The most popular type today is Celepuk jawa (*Otus angelinae*). *Otus angelinae* is the easiest type of owl to be tamed, and it also can be trained for various purposes. In the agricultural sector, it is often used as a pest control, specifically for mice and rat [2]. Using Owls to control rat is more effective than rat hunting or using rat poison. A pair of owls can protect 25 hectares of rice crops from rat. Within a year the owls can prey on 1300 rats. In terms of cost, rat control's cost by using owls is lower by 50 percent compared to by poison. Hence, owls breeding can become a lucrative business opportunity.



The low population of owls (*Otus angelinae*) is influenced by several factors. One of them is the low number of juvenile owls who are able to reach adult age. In the mating season, *Otus angelinae* females can produce as many as 6 eggs, but only 3 to 4 of them who are able to survive into adult owls. In addition, even though the oldest owlet usually becomes a powerful owl, the youngest owlet often has the weakest growth result. Thus, it grew less normal or dies.

Attempts to breed owls can be done by the optimization of the physiological condition of the owl's reproductive system. This can be done with turmeric powder supplementation. Previous study showed that the administration of turmeric powder is capable to accelerate the sexual maturity of female quail [3]. Turmeric powder supplementation can also improve the hierarchy of ovarian follicles in quail [4] and chickens [5], this is because of the active compound in turmeric that is hepatoprotective, which optimize the function of the liver in the synthesis vitellogenin (precursor yolk). Turmeric contains curcumin powder as much as 7.97%, which works to improve liver function [6]. The content of phytoestrogens in turmeric powder is 6.79% [6]. Phytoestrogens have estrogenic effects. It is able to make a bond with estrogen receptors, which leads to the increase of vitellogenin synthesis [7,8]. Vitellogenin carried out through the bloodstream to the ovary, so it can improve follicular hierarchy and increase the number of eggs produced. The increased accumulation of the material forming the yolk inside the follicle also induces the increased embryo source of nutrients, so the embryo develops more optimal. Similarly, according to previous study by [3], a good development of embryo will also lead to a good physiology and immune system. Curcumin acts as an antioxidant, anti-inflammatory, antibacterial, and antiviral [9].

Based on those previous studies, the research on optimizing the reproduction of endangered species of Celebuk jawa (*Otus angelinae*) with turmeric powder could be used as an attempt to bioconservation.

2. Methods

The study was conducted in the laboratory of Biological Structure and Function of the Department of Animal Biology, Faculty of Science and Mathematics, University of Diponegoro. A total of 2 female *Otus angelinae* and 2 male *Otus angelinae* aged 3 months were divided into two experimental groups, namely the control group and the group treated turmeric powder 108 mg/owl/day, which were mixed in a feed. The feed is catfish meat weighing 15 g/day in the morning and evening. The treatment was given every day, for 1 month. Descriptive analysis was done on the development of ovarian follicles hierarchy of female *Otus angelinae*, while the testis organ was observed for the male. Both the female's and male's body weight, liver weight and the length of ductus reproduction were also observed.

3. Results and Discussion

The results of the research supplementation of turmeric powder on the male reproductive organs *Otus angelinae* showed the following results:

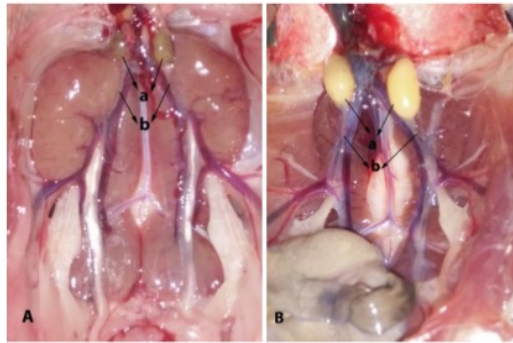


Figure 1. Testis *Otus angelinae* control (A) and which treated by turmeric powder (B). a. testis, b. vas deferens

The results of the research granting turmeric powder to the female reproductive organs *Otus angelinae* showed the following results

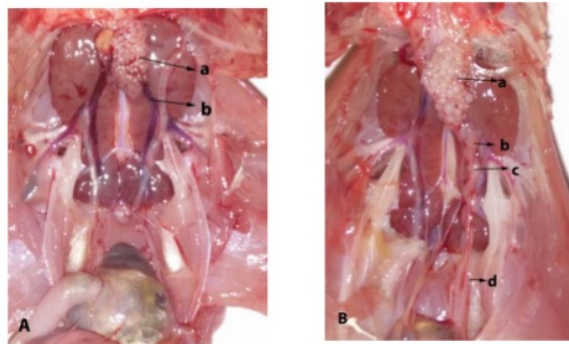


Figure 2. *Otus angelinae* reproduction system, (A) control and (B). treatment with turmeric powder a. ovary, b. infundibulum, c. magnum, d. uterus

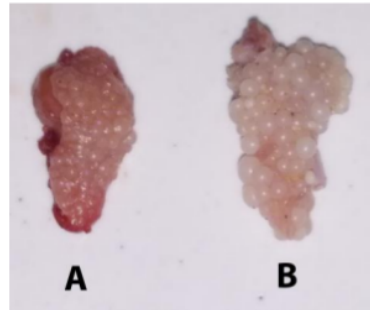


Figure 3. Follicle ovarium *Otus angelinae*. (A) control and (B) treatment by turmeric powder

The addition of turmeric powder does not increase the body weight, liver weight, the length of ductus reproduction, ovarium weight, testes weight *Otus angelinae*

Table 1: The measurement of body weight, liver, the length of ductus reproduction ovarium and testis of *Otus angelinae* male and female at control and which supplemented by turmeric powder

Parameter	Male		Female	
	Control	Treatment	Control	Treatment
Body weight (g)	9	9	9	9
Liver weight (g)	2.32	2.21	2.06	3.92
The length of ductus reproduction (cm)	3.2	5.6	6.5	7.5
Ovary weight (g)			0.13	0.24
Testis weight(g)	0.18	0.25		

K : Control

P : *Otus angelinae* which supplemented by turmeric powder

Based on Figure 1, male *Otus angelinae* has a pair of oval-shaped testes respectively located at the front of the upper lobes of the kidney. In untreated male *Otus angelinae*(control), aged three months, the testes weights 0.18 g. This is in accordance with the opinion which states that owl's testes during non-breeding season are very small. Turmeric powder supplementation affects the growth of the male reproductive organs. The weight of the testes in males *Otus angelinae* three months of age treated with turmeric powder for 1 month at 0.25 g, was approximately 1.5 times bigger than the control, and the color of the testis is yellow.

Testicular growth and reproductive organs occurs along with the development of sexual maturity. Sexual maturity is regulated by sex hormones. Gonadotropin-releasing hormone from the hypothalamus stimulate FSH (Follicle Stimulating Hormone) secretion. FSH stimulates cells to divide by mitosis of spermatogonia several times and ended with meiotic division to produce spermatids. FSH stimulates Sertoli cells to produce substances that can stimulate the spermiogenesis (spermatid differentiation into sperm). FSH and Sertoli cells are also stimulated by testosterone produced by the Leydig cells. Testosterone is a hormone that stimulates the growth and development of reproductive organs.

Besides hormonal factors, the growth of reproductive organs is also influenced by nutritional factors. Nutrition affects various aspects of reproduction, including maturity sexual and testicular growth. Effect of turmeric powder to the development of the testes is suspected because of the curcumin and β -carotene. The content of curcumin in turmeric powder is up to 7.97% [4]. Curcumin has a role as an antioxidant and anti-inflammatory [10,11]. Curcumin also plays a role in cell regeneration [12].

The analysis results of the content of β -carotene in turmeric powder amounted to 40.45 mg/100 mg. β -carotene is an antioxidant exogenous. Utilization of exogenous antioxidant compounds effectively is necessary to prevent the occurrence of oxidative stress. Exogenous antioxidant is a preventive defense system, where the system is the antioxidant works by cutting the chain reaction of free radical oxidation. β -carotene is a chain-breaking antioxidant. It is also a lipophilic which can play a role in sperm cell membrane to prevent lipid peroxidation. The study in rabbits showed that β -carotene can increase the male reproductive system and can support fertilization, increasing the motility and viability of spermatozoa [13]. Provision of β -carotene improves the quality of cement [14,15].

Based on Figure 2, the reproductive organs in female *Otus angelinae* consist of one ovarian that form hierarchy follicle. Hierarchy of follicles in the control (Figure 2A) shows undeveloped ovarian, which weights 0.13 g. Supplementation of turmeric powder is able to stimulate the growth of ovarian hierarchy, so that the weight of the ovaries reach to 0.25 g, although it has not seen any mature follicles. Female reproductive system depends on a complex hormonal mechanism. Gonadotropin hormone produced by the anterior pituitary consists of follicle stimulating hormone (FSH) and luteinizing hormone (LH). FSH hormones affect the growth of young follicles become mature follicles. Besides oocytes, in the follicle that is growing, there are some theca cells and granulosa cells. Furthermore, the FSH hormone also affects the secretion of estrogen and progesterone steroid that is produced by cells theca and granulosa cells, which are essential for the formation of the yolk. Through the blood stream estrogen is taken to liver. Liver has many estrogen receptors in the cytoplasm. Estrogen will further induce the synthesis vitellogenin (precursor yolk). The results showed that administration of turmeric powder in quail [3,4] in laying hens [5] can increase the biosynthesis vitellogenin in the liver, due to their content of phytoestrogens in powder turmeric as much as 6.79%, which has estrogen-like effect of inducing the formation of the yolk precursor [4].

The result in Table 1 showed that the addition of turmeric powder does not increase the body weight of both the female and male *Otus angelinae*. Based on the observation of the liver weight, the results showed that the liver of the *Otus angelinae* females treated with turmeric powder has the greatest weight, namely 3.92 g (Table 1). This indicates an increase in liver activity in the synthesis of the material that forming the yolk. Furthermore, the material of forming the yolk taken to liver to fill the follicle hierarchy as egg yolks, until mature follicles, while the addition of turmeric powder does not affect the liver weight of male *Otus angelinae* because they do not have vitellogenin. The addition of turmeric powder supplement could increase the length of the reproductive organ in female and male *Otus angelinae*, this is proved that the reproduction organ grew synergically with the development of both testes and ovarium to support the reproduction process. In conjunction with the development of the ovarium follicle hierarchy in female *Otus angelinae* and testes in male *Otus angelinae*, there was an increase in the ovarium and testes weight.

4. Conclusion

Based on the results of the study, it can be concluded that supplementation of turmeric powder can accelerate the development of reproductive organs of male and female *Otus angelinae*.

Acknowledgment

This article was part of the results of research funded by PNPB- RPP 2016. Our gratitude goes to the Directorate General of Higher Education and LPPM-Undip.

References

- [1] Kitowski I (2013) Winter diet of the barn owl (*Tyto alba*) and the long-eared owl (*Asio otus*) in Eastern Poland. *North-Western Journal Of Zoology* **9** (1): 16-22
- [2] Meyrom K, Motro Y, Leshem Y, Aviel S, Izhaki I, Argyle F and Charter M (2009) Nest-Box use by the Barn Owl *Tyto alba* in a Biological Pest Control Program in the Beit She'an valley Israel. *Ardea* **97**(4) 463-467
- [3] Saraswati TR and Tana S (2016) Effect Of Turmeric Powder Supplementation Upon The Age Of Sexual Maturity, Physical, And Chemical Quality Of The First Japanese Quail (*Coturnix Japonica*) Egg *Biosaintifika : Journal of Biology and Biology education* **8** (1).
- [4] Saraswati TR, Manalu W, Ekastuti DR, Nastiti K (2013a) Increased Egg Production of Japanese quail (*Coturnix japonica*) by Improving Liver Function Through Turmeric Powder Supplementation. *International journal of poultry Science* **12**(10) 601-614.
- [5] Saraswati TR, Manalu W, Ekastuti DR, Nastiti K (2014) Effect of Turmeric Powder to Estriol and Progesterone Hormon Profile of laying Hens During One Cycle of Ovulation. *International journal of Poultry Science* **13**(9) 504-509.
- [6] Saraswati TR, Manalu W, Ekastuti DR, Nastiti K (2013b) The Role of Turmeric Powder in Lipid Metabolism and the Effect on The Quality of The First Quail's Egg. *The Journal of The Indonesian tropical Animal Agriculture* **38** (2):123-130.
- [7] Levi L, Pekarski I, Gutman E, Fortina P, Hyslop T, Biran J, Levavi B, Lubzens E (2009) Licensee BioMed Central Ltd.<http://www.biomedcentral.com/1471-2164/10/141>.
- [8] Ravindar PN, Babu KN, Sivaraman K (2007) Turmeric. The Genus Curcuma. CRC Press. London, New York.
- [9] Aggarwal BB, Sundaram C, Malani N, Ichikawa H (2006) Curcumin: The Indian Solid Gold. *SVNY-Aggarwal* 16:3.
- [10] Namratha K, Shenai P, Chatra.L, Rao PK, Veena KM, Prabhu RV (2013) Antioxidant and Anticancer Effect of Curcumin –A Review *J Contemp Med* **3**(2): 136-143.
- [11] Servet A, Fatih T, Levent G, Akgul A, Erkan S, Ozkan, Ozalkan M.D (2016) The Anti-inflammatory and Antioxidant Effect of Curcumin in Middle Ear Infection **27**(5) 494-497.
- [12] Sanivarapu R, Vallabhaneni V, and Verma V (2016) The Potential of Curcumin in Treatment of Spinal Cord Injury. *Neurology Research International*.
- [13] Orazizadeh M, Khorsandi L, Absalan F, Hashemitabar M, Daneshi E (2014) Effect of beta-carotene on titanium oxide nanoparticles-induced testicular toxicity in mice. *J Assist Reprod Genet* **31**(5):561-8.
- [14] Baghdadi HH, Kedwany FS, Yousef MI, Demerdash FM (2004) Role of alpha-tocopherol and beta-carotene in ameliorating the fenvalerate-induced changes in oxidative stress, hemato-biochemical parameters, and semen quality of male rats *J Environ Sci Health* **39**(3) 443-59.
- [15] Shalaby F and Missiry MA (2000) Role of beta-carotene in ameliorating the cadmium-induced oxidative stress in rat brain and testis *J Biochem Mol Toxicol* **14**(5) 238-43.

Optimization of the development of reproductive organs celepuk jawa (*Otus angelinae*) owl which supplemented by turmeric powder

ORIGINALITY REPORT

7%

SIMILARITY INDEX

6%

INTERNET SOURCES

3%

PUBLICATIONS

5%

STUDENT PAPERS

PRIMARY SOURCES

1	Submitted to Queen's University of Belfast Student Paper	1%
2	repository.unpad.ac.id Internet Source	1%
3	Submitted to University of Houston System Student Paper	1%
4	pinnacle.allenpress.com Internet Source	<1%
5	www.scribd.com Internet Source	<1%
6	easystar.soundwavedev.net Internet Source	<1%
7	Fatemeh Alizadeh, Maryam Javadi, Ali Akbar Karami, Fereshteh Gholaminejad, Maria Kavianpour, Hossein Khadem Haghghian. "Curcumin nanomicelle improves semen parameters, oxidative stress, inflammatory	<1%

biomarkers, and reproductive hormones in infertile men: A randomized clinical trial",
Phytotherapy Research, 2018

Publication

8

Muhammad Nur, Maryam Resti, Fajar Arianto, Zaenul Muhlisin et al. "Development of ozone technology fish storage systems for improving quality fish production", 2014 International Symposium on Technology Management and Emerging Technologies, 2014

Publication

<1%

9

lipi.go.id

Internet Source

<1%

10

repositorio.unesp.br

Internet Source

<1%

11

"Abstract", Journal of Ornithology, 2006

Publication

<1%

12

complete.bioone.org

Internet Source

<1%

13

www.scopemed.org

Internet Source

<1%

Exclude quotes Off

Exclude matches Off

Exclude bibliography Off

Optimization of the development of reproductive organs celepuk jawa (otus angelinae) owl which supplemented by turmeric powder

GRADEMARK REPORT

FINAL GRADE

/0

GENERAL COMMENTS

Instructor

PAGE 1

PAGE 2

PAGE 3

PAGE 4

PAGE 5

PAGE 6

PAGE 7
