

CALCULATION of the CEREBRAL HEMORRHAGE VOLUME USING ANALYSIS of COMPUTED TOMOGRAPHY IMAGE

by Kusworo Adi

Submission date: 20-Jan-2020 01:20PM (UTC+0700)

Submission ID: 1243952659

File name: EMORRHAGE_VOLUME_USING_ANALYSIS_of_COMPUTED_TOMOGRAPHY_IMAGE.pdf (1.72M)

Word count: 2053

Character count: 11357



CALCULATION of the CEREBRAL HEMORRHAGE VOLUME USING ANALYSIS of COMPUTED TOMOGRAPHY IMAGE

Cory Amelia*

Magister of Physics, Faculty of Science and Mathematics, Diponegoro University, Semarang, Indonesia
coryamelia@st.fisika.undip.ac.id

Kusworo Adi

Department of Physics, Faculty of Science and Mathematics, Diponegoro University, Semarang, Indonesia
kusworoadi@fisika.undip.ac.id

Catur Edi Widodo

Department of Physics, Faculty of Science and Mathematics, Diponegoro University, Semarang, Indonesia
catur.ediwidodo@fisika.undip.ac.id

Manuscript History

Number: IJIRAE/RS/Vol.04/Issue06/JNAE10084

Received: 07, May 2017

Final Correction: 20, May 2017

Final Accepted: 28, May 2017

Published: June 2017

Citation: Amelia*, C.; Adi, K. & Widodo, C. E. (2017), 'CALCULATION of the CEREBRAL HEMORRHAGE VOLUME USING ANALYSIS of COMPUTED TOMOGRAPHY IMAGE', Master's thesis, Department of Physics, Faculty of Science and Mathematics, Diponegoro University, Semarang, Indonesia.

Editor: Dr.A.Arul L.S, Chief Editor, IJIRAE, AM Publications, India

Copyright: ©2017 This is an open access article distributed under the terms of the Creative Commons Attribution License, Which Permits unrestricted use, distribution, and reproduction in any medium, provided the original author and source are credited

Abstract-- A study of cerebral hemorrhage detection using computed tomography with head image has been done. The process after detection is the determination of the area and volume of hemorrhage. Image processing techniques used are Segmentation of Otsu method. This segmentation method successfully obtained binary image and proceed with morphology process, with output image result of morphology operation calculated the area. After the area of the object on each image slice is obtained, the next step is the volume calculation. Volume calculation is done by summing the area of the object on each slice then the result multiplied by the slice thickness. The result of the use of image processing techniques can be offered as a substitute for manual calculating by doctors.

Keywords— Cerebral hemorrhage, segmentation of otsu method, computed tomography, area and volume.

I. INTRODUCTION

Brain is the most complex organ because it serves to control physiological activity, such as motion system, heart rate, memory and mood. The brain is also a central controlling organ to move the working system of other organs. Damage to the work system of the brain, of course, can disrupt the work system of the body of other parts that will impact on neurological health disorders, paralysis and mental disorders or thoughts of a person. Rupture of blood vessels of the brain will cause hemorrhage. Hemorrhage in the brain can cause death if not treated immediately so early detection is needed for diagnostic purposes [1].

Cerebral hemorrhage is the first cause of death at the age of 15-24 years, third sequence after heart disease and cancer. Detecting the correct location and type of hemorrhage in the early stages can help the patient's life [2]. The modalities can be used for early detection of cerebral hemorrhage is CT scan [3,4].

Early detection of cerebral hemorrhage by CT scan should be able to calculate the area and volume of hemorrhage as it is indispensable for the cerebral hemorrhage to be treated immediately. There are several image processing techniques can be used to detect the hemorrhage area is the Otsu method. The Otsu method is a fairly accurate segmentation method in obtaining an area that is a segmented object using a grayscale histogram and can be used for the determination of the threshold value automatically from a gray scale image [5].

In addition to Otsu methods, there are other image processing methods that can be used to detect hemorrhage areas such as segmentation method of threshold adaptive and case-based reasoning (CBR) [6]. Detection of hemorrhage in the ventricle of the brain can also be done by a set level segmentation method [7]. Detection with three segmentation methods is fuzzy c-means method, region method-based active contour, and proposed fuzzy method based on set level segmentation [8]. The segmentation method of watershed, which continues for feature extraction, can use the Gray Level Co-occurrence Matrix (GLCM) algorithm, and to classify the types of hemorrhage in the brain using artificial neural network algorithms [9]. In this paper the use of image processing methods in order to separate the object with the background so that it can determine the area and volume of hemorrhage.

II. MATERIALS AND METHOD

2.1 MATERIALS

The image data obtained from scanning CT Scan with Siemens brand 64 slice. The image used in the image is ct scan of axial piece head with bitmap format with 512x512 matrix size and field of view (fov) about 187 mm x 187mm, slice thickness of 2.5 mm. The image to be segmented is just the image that there is hemorrhage. Examples of normal images and cerebral hemorrhage in CT scan can be seen in Fig 2.1.

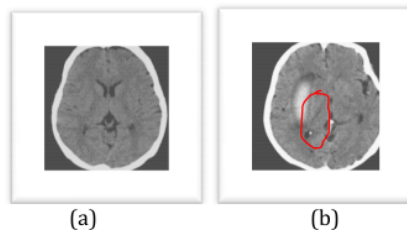


Fig. 2.1. Head CT scan image (a) normal (b) Intraparenchymal Hemorrhage

2.2 METHOD

The several stages performed in this study are as follows:

1. The head image with bitmap format is read by matlab
2. Selected imagery that there is cerebral hemorrhage from all the slices
3. The selected image is segmented by otsu method on each slice
4. Followed by an operation aimed at refining the segmentation results and eliminating the emerging noise
5. Hemorrhage area is calculated from the output of morphological process, the calculation of area using the equation

$$Area = \frac{\sum_{i=1}^N \sum_{j=1}^M f(i,j)}{r^2} \quad (2.1)$$

6. Hemorrhage area of each slice is summed and divided by the spatial resolution of the image
7. Volume is obtained from the total area of hemorrhage multiplied by slice thickness with value 2,5 mm, using the equation

$$Volume = \sum_{k=1}^W A(k) \times s \quad (2.2)$$

III. RESULTS AND DISCUSSION

The type of cerebral hemorrhage used in this study belongs to the type of Intraparenchymal Hemorrhage. Hemorrhage is seen from the image of the head scan, furthermore the image segmentation of head using the otsu method. Otsu method is one of thresholding method. The purpose of the method is to divide the gray level graphic histogram into two different regions automatically without requiring the user's help to enter the threshold value [5].

Segmentation processes are performed using the matlab programme and the image used for segmentation is a CT scan image. CT head image with hemorrhage on slice 26 until slice 37 before segmentation can be seen in Fig.3.1.

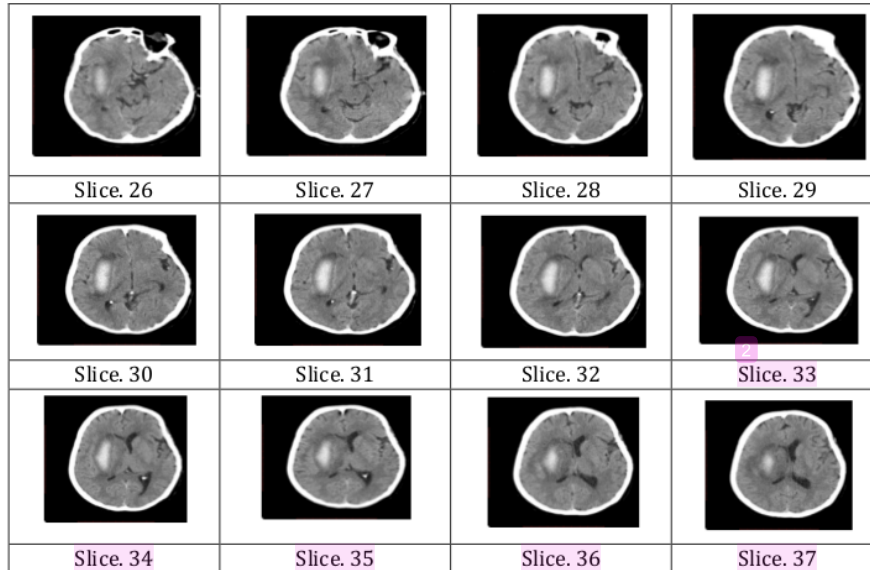


Fig.3.1 Original head image with hemorrhage

The result of segmentation of otsu method can separate object with its background, that is brain hemorrhage and brain. The next step is followed by morphological operations to improve the segmentation results and eliminate the noise and eliminate the undesirable area. The result of segmentation with otsu method and morphological operation is binary image. The binary image obtained is 12 slices of a total of 64 head image slices, starting from slice 26 to slice 37. The binary image is used for calculating the area of hemorrhage in the brain by summing all white objects with pixels of value is 1. Binary image of the segmentation result scan be seen in the fig.3.2.

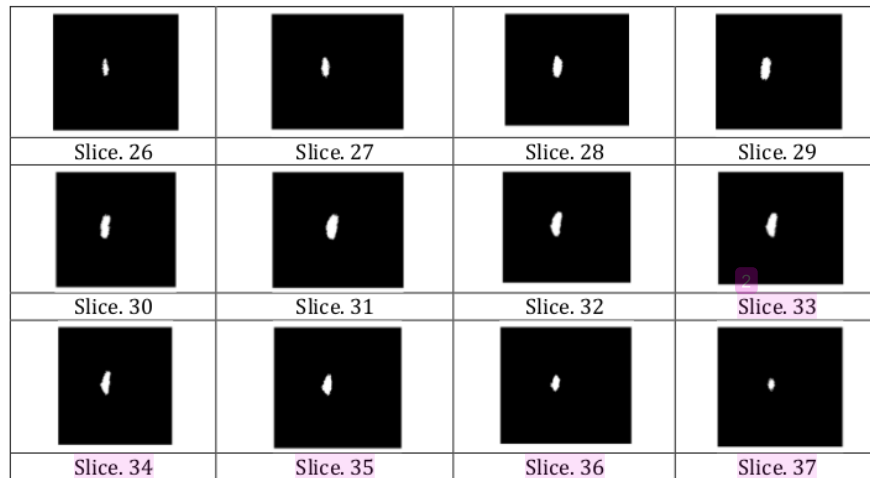


Fig.3.2 Binary image of segmentation result

The area of hemorrhage obtained on each slice is 1223 (slice 26), 1919 (slice 27), 2776 (slice 28), 3704 (slice 29), 3226 (slice 30), 3441 (slice 31), 3432 (slice 32), 3249 (slice 33), 2857 (Slice 34), 2330 (slice 35), 1619 (slice 36), and 963 (slice 37). The area is summed so as to obtain the total area of hemorrhage is 30079.

The total area value obtained is still in pixel units, so as to convert it into mm^2 units, then the result is divided by image spatial resolution is 2,7380 pixels/mm. Obtained total area value after divided by image spatial resolution using equation 2.1. So that obtained value of $4012.4 mm^2$. The cerebral hemorrhage volume is $10031 mm^3$ was calculated by equation 2.2.

The head image in brain hemorrhage can be well segmented, and to know the region and area of hemorrhage segmented can be seen from the visualization of the segmentation results in Fig. 3.3. The segmented region is visualized in red and the region is a hemorrhage area.

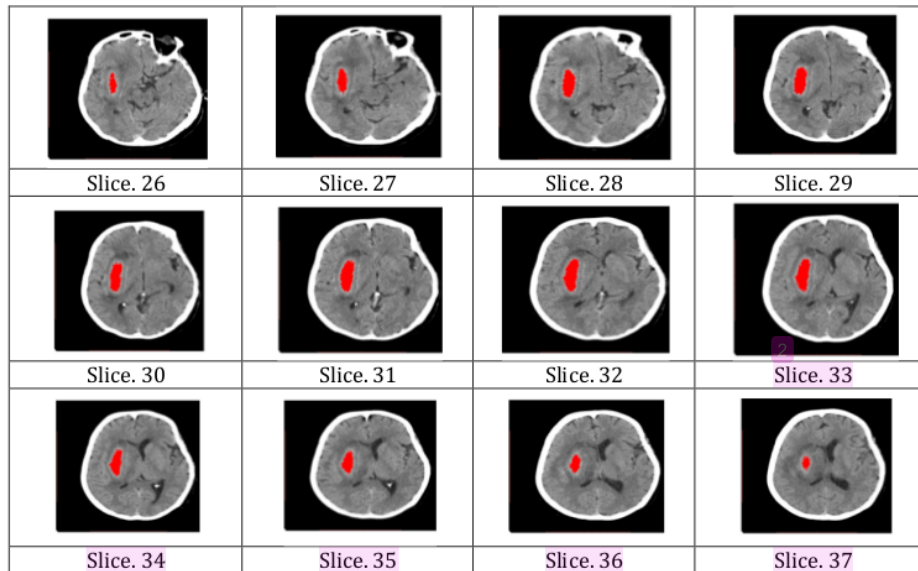


Fig.3.3 Image of the head with visualization of the segmentation results

IV. CONCLUSION

From the image evaluation result of each slice produced, we conclude that the use of otsu method and morphological operation for image segmentation process can be well implemented. The segmentation results can be used for the determination of the hemorrhage area so that the hemorrhage volume can be calculated. The size of the hemorrhage volume can be used by the physician for further medical treatment.

REFERENCE

1. Fatima, M.S., Naaz, S, and Anjum, K., 2015, Diagnosis And Classification Of Brain Hemorrhage Using CAD System, *Department Of E & CE, Bheemanna Khandrre Institute Of Technology Bhalki, Bidar, India.*
2. Shahangian, B., and Pourghassem, H., 2013, Automatic Brain Hemorrhage Segmentation and Classification in CT scan Images, *Iranian Conference on Machine Vision and Image Processing (MVIP), IEEE,*
3. Datta, A., Datta, A., and Biswas, B., 2011, A Fuzzy Multilayer Perceptron Network based detection and classification of lobar intra-cerebral hemorrhage from Computed Tomography images of brain, *International Conference on Recent Trends in Information System, IEEE pages 257-262.*
4. Bhadauria, H.S., and Dewal, M.L., 2012, Efficient Denoising Technique for CT Images to Enhance Brain Hemorrhage Segmentation, *Jurnal of Digital Imaging 25:782-791.*
5. Otsu, N., 1979, *A Threshold Selection Method From Gray-Level Histograms*, Mathematical Engineering Section, Information Science Division, Electrotechnical Laboratory, Chiyoda-Ku, Tokyo 100, Japan.
6. Zhang, Y., Chen, M., Hu, Q, and Huang, W., 2013, Detection And Quantification Of Intracerebral And Intraventricular Hemorrhage From Computed Tomography Images With Adaptive Thresholding And Case-Based Reasoning, *International Journal Computer Assisted Radiology and Surgery.*



7. Prakash, K.N.B., Zhou, S., Morgan, T.C., Hanley, D.F, and Nowinski, W.L., 2012, Segmentation and Quantification of Intra-Ventricular / Cerebral Hemorrhage in CT Scans by Modified Distance Regularized Level Set Evolution Technique, *International Journal Computer Assisted Radiology and Surgery*, 7:785-798.
8. Bhadauria, H.S., and Dewal, M.L., 2014, Intracranial Hemorrhage Detection Using Spatial Fuzzy C-Mean and Region-Based Active Contour on Brain CT Imaging, *Signal Image and Video Processing* 8(2):357-364.
9. Mahajan, R., and Mahajan, P.M., 2016, Survey On Diagnosis Of Brain Hemorrhage By Using Artificial Neural Network, *International Journal of Engineering Research*, 4: 109-116.

CALCULATION of the CEREBRAL HEMORRHAGE VOLUME USING ANALYSIS of COMPUTED TOMOGRAPHY IMAGE

ORIGINALITY REPORT

10%

SIMILARITY INDEX

5%

INTERNET SOURCES

9%

PUBLICATIONS

6%

STUDENT PAPERS

PRIMARY SOURCES

- 1** creativecommons.org 2%
Internet Source
- 2** Sahiner, Berkman, Lubomir M. Hadjiiski, Heang-Ping Chan, Jiazheng Shi, Ted Way, Philip N. Cascade, Ella A. Kazerooni, Chuan Zhou, and Jun Wei. "", Medical Imaging 2007 Computer-Aided Diagnosis, 2007. 2%
Publication
- 3** "Computational Science and Technology", Springer Science and Business Media LLC, 2019 2%
Publication
- 4** Manoj Diwakar, Prabhishek Singh. "CT image denoising using multivariate model and its method noise thresholding in non-subsampled shearlet domain", Biomedical Signal Processing and Control, 2020 1%
Publication
- 5** Submitted to University of New Orleans
Student Paper

1%

6

Submitted to University of Northampton

Student Paper

1%

7

refubium.fu-berlin.de

Internet Source

1%

8

Submitted to University of Zakho

Student Paper

1%

9

www.ijsr.in

Internet Source

1%

Exclude quotes Off

Exclude matches < 1%

Exclude bibliography Off

CALCULATION of the CEREBRAL HEMORRHAGE VOLUME USING ANALYSIS of COMPUTED TOMOGRAPHY IMAGE

GRADEMARK REPORT

FINAL GRADE

/0

GENERAL COMMENTS

Instructor

PAGE 1

PAGE 2

PAGE 3

PAGE 4

PAGE 5
