

Sensitivity Evaluation of Magnetization Transfer Ratio for Diagnosing Intractable Mesial Temporal Lobe Epilepsy with Normal MRI: Experience in Indonesia

by Hermina Sukmaningtyas

Submission date: 19-Feb-2020 08:35AM (UTC+0700)

Submission ID: 1259855849

File name: poral_Lobe_Epilepsy_with_Normal_MRI__Experience_in_Indonesia.pdf (278.66K)

Word count: 4114

Character count: 21437

Sensitivity Evaluation of Magnetization Transfer Ratio for Diagnosing Intractable Mesial Temporal Lobe Epilepsy with Normal MRI: Experience in Indonesia

HERMINA SUKMANINGTYAS^{1,6}, JACUB PANDELAKI^{2,7}, MEIRA DEWI KUSUMA ASTUTI^{3,6}, DYAH FAUZIAH^{4,8}, RIWANTO^{5,6}, ZAINAL MUTTAQIN^{5,6}

¹Department of Radiology, Faculty of Medicine, Diponegoro University, Semarang, Indonesia

²Department of Radiology, Faculty of Medicine, University of Indonesia, Jakarta, Indonesia

³Department of Anatomical Pathology, Faculty of Medicine, Diponegoro University, Semarang, Indonesia

⁴Department of Anatomical Pathology, Faculty of Medicine, Universitas Airlangga, Surabaya, Indonesia

⁵Department of Surgery, Faculty of Medicine, Diponegoro University, Semarang, Indonesia

⁶dr. Kariadi General Hospital, Semarang, Indonesia

⁷Cipto Mangunkusumo Hospital, Jakarta, Indonesia

⁸dr. Sutomo Hospital, Surabaya, Indonesia

Correspondence to Dr. Hermina Sukmaningtyas, Email: hermina_rad@yahoo.co.id, hermina_rad@fk.undip.ac.id, Tel. 62-08112746000

ABSTRACT

Background: Standardized Magnetic Resonance Imaging (MRI) cannot show the cause of intractable mesial temporal lobe epilepsy (MTLE) in 20-30% cases. These normal MRI patients need advanced imaging to visualize the epileptogenic zone to determine lateralization for surgery.

Aim: To investigate sensitivity of Magnetization Transfer Ratio (MTR) in detecting lateralization and correlate the MTR with histopathological features of surgical resection on intractable MTLE.

Method: Twenty-three consecutive surgical candidates with intractable focal temporal epilepsy, as determined with ictal scalp video-EEG and standardized MRI, were examined with MTR. The MTR was measured in hippocampus. The data were then compared with a healthy control group. Histopathological results of surgical specimens were stained with NeuN, GFAP, and Neuropeptide Y to assess neuronal loss, gliosis and axonal/Mossy Fiber sprouting.

Results: Ten of 23 patients had normal MRI. MTR patients had lower average than control. Despite MTR had no correlation with neuronal loss, gliosis and axonal fiber sprouting; its sensitivity and specificity reached approximately 81.8% and 68.2% respectively; and concordance with EEG on 6 out of 10 patients.

Conclusion: MTR has fairly good sensitivity and EEG concordance, but low specificity so the result may be indicative for diagnostic accuracy to determine MTLE lateralization with normal MRI.

Keywords: MTR, Intractable Mesial Temporal Lobe Epilepsy, Normal MRI

INTRODUCTION

Epilepsy is a chronic brain disorder characterized by recurrent spontaneous seizures, predisposing with accompanying failure of neurobiology, cognitive, psychological and social functioning¹. Mesial Temporal Lobe Epilepsy (MTLE) is one of the most common forms of epilepsy in adulthood which causes an intractable epilepsy, type of epilepsy suffered by nearly 20% of all epilepsy patients². This incident is also experienced by Indonesian people, the number of whom suffering from epilepsy has reached about 1.1 million out of 220 million people (assuming the epilepsy rate of 0.5% out of the total population), with 276 to 386 thousands are intractable (refractory) epilepsy against anti epileptic drug (AED)³.

Intractable MTLE mostly caused by hippocampal sclerosis, and surgery can commonly give satisfactory result. This surely requires the accuracy of the diagnosis in determining the location and lateralization of the epileptogenic zone in order to provide better postoperative outcomes. Determining lateralization of epileptogenic zone can be made by neuroimaging that has an important role to aid in diagnosis, therapeutic determination, surgical planning even as a predictor of the efficacy of epilepsy patients' therapy⁴.

This can be commonly done by using MRI, a noninvasive examination that has the advantage of good

and sensitive anatomic resolution in recognizing small structural lesions, especially high resolution MRI (≥ 1.5 Tesla). However, approximately 20-30% of intractable focal epilepsy patients cannot be detected with standard MRI⁵.

The development and application of additional quantitative techniques on MRI such as Diffusion Weighted Imaging (DWI), Magnetization Transfer Imaging (MTI), T2 Relaxometry, Volumetric MRI, Magnetic Resonance Spectroscopy (MRS) are expected to add to the specificity of qualitative MRI standard in detecting hippocampal sclerosis⁶. The quantitative MRI is particularly useful in cases of bilateral atrophy, unclear unilateral atrophy and symmetrical hippocampal pathology. Volumetric MRI and T2 relaxometry may help detecting Mesial Temporal Lobe Sclerosis (MTLS) to 80%, with 20% of normal detection⁷.

MTI is a method which can give tissue contrast based on spin magnetization between free proton and its bond with protein molecule. MTI studies in epilepsy showed reduced MT ratios in TLE and other types of epilepsy even in patients with normal standard MRI. Some study also obtained a decrease in MT ratio in the extratemporal region, which indicates the involvement of extratemporal spread such as the frontal lobe connected with the temporal lobes. These findings suggest that MTLE is a disease that involves the spread of lesions in white and gray matter, presumably caused by demyelination⁸⁻¹².

Salmenpera, *et al*⁶ found a decrease in MT ratios in an intractable focal epileptic patient whose standard MRI showed no abnormality compared to healthy controls. MTI accuracy data are not available in diagnosing hippocampal sclerosis.

According to Tofts, *et al*.⁸ the decrease in MT ratios is thought to reflect gliosis and neuronal loss. The study by Eriksson, *et al*.¹³ found a decrease in MT ratios although there was no significant correlation between MT ratios with histopathology. The limitations of these studies are very small sample (5 subjects) so the results are not convincing, so a deeper study of the MT relationship with histopathology is required. Eriksson's research is not only focused on hippocampal sclerosis. Unlikely, Li, *et al*.⁹ showed different results, MT ratios were not able to determine lateralization of TLE, but this study was conducted on a small sample and was not proven by histopathological examination. The Lascola, *et al*.¹⁴ study obtained a correlation between MT ratios with glial reactivity assessed by immunohistochemistry with the staining of glial fibrillary acidic protein (GFAP).

In the present study, we sought to investigate sensitivity of MTR in detecting hippocampal sclerosis and correlate the MTR with histopathological features of surgical resection on intractable MTLE. We used NeuN, GFAP, and Neuropeptide Y to assess neuronal loss, gliosis and axonal/Mossy Fiber sprouting in MTLE patients with normal MRI.

MATERIAL AND METHODS

Twenty-three MTLE patients and 10 healthy subjects were enrolled in this research. The healthy subject as control group fulfilled the criteria as follows: no any history of neurological disorder and having normal MRI. All participants provided written informed consents. This study was approved by our local institutional ethics committee, the Health and Medical Research Ethics Committee of Faculty of Medicine Diponegoro University and Kariadi Hospital Semarang Indonesia.

The intractable mesial temporal lobe epilepsy diagnosed according on ILAE criteria. All MTLE subjects met the following inclusion criteria: age \geq 7 years; able to fulfill MRI examination requirements; and able to provide hippocampal surgery specimen for histopathological analysis. Drop out criteria when the surgery's specimen cannot be analyzed histopathologically.

Magnetic Resonance Imaging: MR imaging was performed on 1.5T MR scanner (SignaHDxt 16 Ch, GE Milwaukee USA) at Department of Radiology dr. Kariadi General Hospital and St. Elisabeth Hospital, Semarang Indonesia. The protocol included standardized MRI for MTLE were T1, T2, FLAIR (Fluid Attenuation Inversion Recovery) sequence which perpendicular with hippocampal axis.

Magnetization Transfer Imaging (MTI)

Image Acquisition: T1-weighted and MT images were obtained using a pair of 3D gradient echo acquisitions, without (No Sat) and with (Sat) MT saturation pulses, respectively. Percentage difference ($100 \times [\text{No Sat} - \text{Sat}] / \text{No Sat}$) of MT images were calculated after thresholding above the noise background. MTR maps: TR

= 34 ms, TE = 11 ms, flip angle = 30°, FOV = 256 × 192 rectangular matrix, and axial slice thickness 3 mm. First sequence did not use saturated magnetization transfer, while second sequence used typical saturation for solid component, with very short TR, Gaussian type, duration 7.68-ms, 500° (effective pulse angle) and 1.5-kHz off-resonance.

MTR Map Construction: MTR maps were obtained by processing the data using both an in-house developed script running and under Matlab measurement (Mathworks, Massachusetts, USA).

Region of interest (ROI= 20-30 mm²) were selected on the axial section from a small oval region drawn in 4 locations (2 at head, 1 at body and at tail of each right and left hippocampus) then calculating the average (Figure 1). Adjacent cerebrospinal fluid-containing pixels were avoided in ROIs to reduce the partial volume effects (Figure 1). Determination of which side hippocampus was affected in this study was chosen from MTR with smaller measurement.

Histopathological staining: Haematoxyllin-Eosin (HE), NeuN, GFAP and Neuropeptide Y (Biocare) staining was performed to assess the neuronal loss (NeuN), gliosis (GFAP) and axonal/Mossy Fiber sprouting (Neuropeptide Y). The score of the abnormality was classified as mild grade when there was < 70% of neuronal loss and there was no intensely stained for gliosis or axonal sprouting. While, severe grade was classified when the neuronal loss reached > 70% and there was intensely stained for gliosis or axonal sprouting.

Statistical analysis: The MTR values extracted from 4 ROIs were compared between patients and control using a non parametric statistic. The sensitivity of MTR in detecting hippocampal sclerosis was measured. The association between MTR with neuronal loss, gliosis and axonal sprouting was assessed using Spearman's correlation.

RESULT

Participant characteristics: Participant demographics, clinical characteristics, and MTR values were given in Table 1. The mean of MTLE group age was 24 years, the youngest was 14 years and the oldest was 41 years. In the healthy volunteer group, the mean of age was 31 years (ranging from 26 to 36 years). The mean of age of the healthy volunteer group was older compared to the MTLE group, in which statistical analysis showed no significant difference ($p=0.19$). In MTLE group, 12 subjects were females (52.17%) and 11 were males (47.83%). As in healthy volunteer group most subjects were females (70%), while the number of male subjects was 30%. The average duration of illness period was 12.9 years ranging from 2 to 32 years.

Table 1, 2 and 3 showed data for patient group and the healthy control subject, along with the relevant medical histories and MTR measurement.

EEG and standardized MRI T2: Table 2 and 3 present the results of EEG and lateralization, MRI T2, types, and area of surgery. The EEG examination fulfilled some criteria as MTLE. The details of EEG lateralization were as follows: 8 subjects were right, 12 subjects were left, 2 subjects were normal, and 1 subject was undetermined lateralization.

Next, video monitoring and intracranial EEG were carried out towards normal and undetermined EEG. As a result, the final findings showed 10 right and 13 left EEG lateralization.

The result of T2/FLAIR parameter on 23 MTLE subjects revealed that 11 patients (47.83%) suffered from hippocampal sclerosis (T2/FLAIR hyperintens), 10 patients (43.48%) with subtle T2 (normal MR), 1 patient with dysplasia, and 1 patient with heterotopia. MRI T2 examination showed 4 subjects with right hippocampal sclerosis, 5 subjects with left hippocampal sclerosis, 10 subjects with normal MR, 1 subject with bilateral sclerosis, and 2 subjects with lateralization to the right (dysplasia and heterotopia). On 10 TLE cases with normal MRI, lateralization of 9 patients was determined by EEG monitoring and 1 case intracranial EEG. Furthermore, the location of lesion was identified by PET examination.

MTR analysis: The MTR mean in the patients which was lower than control group, had fairly good sensitivity (80%) and concordance with EEG 6/10 in normal MRI MTLE (Table 3 and 4). Furthermore, MTR had no significant correlation with grading of neuronal loss, gliosis and axonal sprouting.

Histopathological analysis: Histopathological examination in this research, a complete structure of hippocampal, was not found in all samples however an enthorinal cortex structure, subiculum and CA1 were found. On hippocampal's surgery material, it was found that all neuronal loss and gliosis were prominent on CA1 of all subjects (probably hippocampal sclerosis). Based on the histopathological analysis, it was found out that there were 11 subjects with hippocampal sclerosis and 12 with Focal Cortical Dysplasia (FCD). In FCD group, 4 subjects showed hippocampal with hyperintens lesion on T2 MRI. From ten subjects with normal MRI, 4 subjects (40%) were considered as hippocampal sclerosis while 6 subjects (60%) showed histopathology results of FCD. The former group had different levels of immunohistochemistry examination: 1 subject with mild gliosis, 50% neuronal loss,

and severe axonal sprouting; 1 subject with mild gliosis, 70% neuronal loss, and mild axonal sprouting; and 2 subjects with severe gliosis, 80% neuronal loss, and severe axonal sprouting.

The sensitivity of MTR to detect hippocampal sclerosis: MTR in MLTE group showed lower result, and significant difference compared with healthy volunteers (Table 1 and 3). The sensitivity of MTR was evaluated based on the result of cut off point (COP) with Area Under Curve (AUC) ≥ 0.7 that was considered appropriate for an analysis. The COP of MTR was 17.85 and AUC=0.74. The sensitivity, specificity, positive predictive value, and negative predictive value were 81.2%, 68.2%, 56.2% and 88.2% respectively (Table 4). There were no significantly correlation between MTR with grading of neuronal loss ($r=0.216$; $p=0.322$), gliosis ($r=-0.119$; $p=0.587$), and axonal sprouting($r=-0.185$; $p=0.398$)

Figure 1 . ROI's placement in hippocampal location

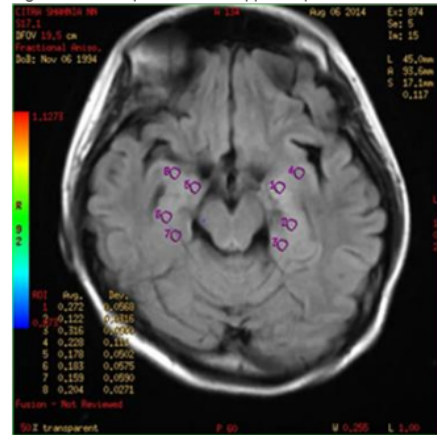


Table 1. Participants characteristic

	Healthy control	MTLE	p
N	10	23	
Mean age, years (min-max)	31 (26-36)	24 (14-41)	0.19
Gender, male/female	3/7	11/12	
Disease duration, years (min-max)	NA	12.9 (2-32)	
Mean MTR	25.5%	16.66%	0.007

Table 2. Clinical characteristics of patients, EEG, MRI and histopathological findings

Patient/ Sex/ Age (Y)	Age at onset (Y)	Duration of illness (Y)	Scalp EEG	Video EEG	Standard MRI/T2	Surgery	Histopathological Finding
1/ F/ 25	8	17	Lt		Lt	Lt SAH	Hippocampal sclerosis
2/M/30	18	12	Rt		N	Rt ATL	Hippocampal sclerosis
3/ F/19	9	10	N	Lt	N	Lt SAH	Hippocampal sclerosis
4/ M/26	5	21	Lt		Lt	Lt SAH	Hippocampal sclerosis
5/ F/28	22	6	Lt		N	Lt SAH	Hippocampal sclerosis
6/ F/17	1	16	Lt		Lt and Rt	Lt ATL	Hippocampal sclerosis
7/ M/17	12	5	N	Rt	Rt	Rt ATL	Hippocampal sclerosis
8/F/24	22	2	Lt		Lt	Lt SAH	Hippocampal sclerosis
9/ F/20	6	14	Lt		Lt	Lt ATL	Hippocampal sclerosis
10/ M/24	12	12	Rt	Lt	Lt	Lt ATL	Hippocampal sclerosis
11/ F/40	20	20	Lt		N	Lt SAH	Hippocampal sclerosis
12/ M/14	9	5	Rt		Rt Dysplasia	RTATL	Focal Cortical Dysplasia
13/ M/41	15	26	Rt		Rt Heterotopia	Rt ATL	Focal Cortical Dysplasia
14/ F/34	9	25	Rt		Rt	Rt ATL	Focal Cortical Dysplasia

15/ M/18	16	2	Rt		N	Rt ATL	Focal Cortical Dysplasia
16/ M/16	5	11	Lt		Lt	Lt SAH	Focal Cortical Dysplasia
17/M/24	4	20	N	Rt	Rt	Rt ALT	Focal Cortical Dysplasia
18/ M/17	14	3	Rt		N	Rt ATL	Focal Cortical Dysplasia
19/F/20	7	13	Rt		Rt	Rt ATL	Focal Cortical Dysplasia
20/F/22	12	10	Lt		N	Lt SAH	Focal Cortical Dysplasia
21/ M/37	5	32	Lt		N	Lt SAH	Focal Cortical Dysplasia
22/F/20	15	5	Rt		N	Rt ATL	Focal Cortical Dysplasia
23/F/19	10	9	Lt		N	Lt SAH	Focal Cortical Dysplasia

Rt:Right; Lt: Left; ATL: Anterior Temporal Lobectomy; SAH:Selective Amigdalohippocampectomy; N: Normal

Table 3. EEG, MR and MTR of the Patient

Patient/ Sex/ Age (Y)	Standard T2 MR	EEG	MTR (%)	Lateralization MTR
1/ F/ 25	Lt	Lt	21.3	Rt
2/M/30	N	Lt	16.7	Lt
3/ F/19	N	Rt	19.5	Rt
4/ M/26	Lt	Lt	16.3	Lt
5/ F/28	N	Lt	17.8	Lt
6/ F/17	Lt and Rt	Lt	13.8	Rt
7/ M/17	Rt	RT	17.8	Rt
8/F/24	Lt	Lt	12.4	Lt
9/ F/20	Lt	Lt	10.4	Lt
10/ M/24	Lt	Lt	15.7	Lt
11/ F/40	N	Lt	16.7	Lt
12/ M/14	Rt Dysplasia	Rt	19.3	Lt
13/ M/41	Rt Heterotopia	Rt	18.4	Rt
14/ F/34	Rt	Rt	17.2	Rt
15/ M/18	N	Rt	17.9	Rt and Lt
16/ M/16	Lt	Lt	15.3	Rt
17/M/24	Rt	Rt	16.5	Rt
18/ M/17	N	Rt	19.2	Lt
19/F/20	Rt	Rt	13.4	Rt
20/F/22	N	Lt	14.8	RT
21/ M/37	N	Lt	17.9	Lt
22/F/20	N	Rt	16.0	Lt
23/F/19	N	Lt	18.7	Lt
Mean			16.66	

Table 4. Diagnostic value of MTR to detect hippocampal sclerosis

MRI	Sensitivity	Specificity	PPV (%)	NPV (%)	Accuration
MTR	81.8	68.2	56.2	88.2	72.7
MTR matlab	72.7	63.6	50.0	82.3	66.7

DISCUSSION

In this study, significant reduction of MTR in MTLE patients was found compared with controls, and it was strengthened with quite good sensitivity and lateralization suitability to EEG with normal MRI in detecting hippocampal sclerosis. In contrary, MTR values in this study did not correlate with the degree of neuronal loss, gliosis and axonal sprouting. This findings support a research conducted by Fjaer *et al.*¹⁵ which obtained that MTR correlate with myelin loss in deep white matter. This research also has the same result with the study by Eriksson *et al.*¹³ which found a decrease in MT ratios although there was no significant correlation between MT ratios with histopathology. MT measurements showed sensitivity in detecting edema, loss of cell structure and proteolysis as in multiple sclerosis, ischemia or neoplasm, and glia reactivity.¹⁴ The MTR signal is dependent upon with exchange magnetization between free and bound protons in tissue and this depends upon the integrity of the macromolecular environment.

The appropriateness between MTR with EEG in our study showed higher result (7 out of 10 patients) compared with Rugg-Gunn *et al.*¹⁰ that obtained a decrease in MTR on ELT and a lateralized appropriateness with an EEG of 33% in patients with normal MRI. Salmenpera *et al.*⁵ obtained results that MT had a low ability to detect lesions

in a normal MRI ELT. This is thought to be caused by other etiologies such as the presence of dysplasia, atrophy and neuronal loss, in line with our study that in 10 MTLE patients with normal MRI, 4 patients showed hippocampal sclerosis and 6 patients showed focal cortical dysplasia.

Besides hippocampal sclerosis, intractable epilepsy can be caused by extratemporal epilepsy, which covers almost 30% of cases. MRI examination cannot asses this lesion (Non Lesional Neocortical Epilepsy/NLNE). NLNE caused by FCD is often undetermined by regular MRI examination.

FCD is considered the most often cause of intractable MTLE in children and the second and third in adults, while the etiology of intractable MTLE in adults is hippocampal sclerosis. FCDs occur isolated in adults or children, or can be detected adjacent to hippocampal sclerosis, glioneuronal tumours, vascular malformations or perinatal brain damage.^{16,17} Abnormal radial and/or tangential cortical lamination in the temporal lobe cortex associated to Hippocampal Sclerosis (HS) is now classified as focal cortical dysplasia (FCD) type IIIa in the current ILAE FCD classification. Five variants of FCD type IIIa have been recognized: 1) HS with architectural abnormalities in the temporal lobe; 2) HS with Temporal Lobe Sclerosis (TLS); 3) HS with TLS and heterotopic neurons in subcortical white matter; 4) HS with TLS and small "lentiform"

heterotopias in subcortical white matter; and 5) HS without TLS but with small "lentiform" subcortical heterotopias.¹⁸ Temporal lobe epilepsy due to dysplasia type IIIa is a common epileptic disorder and a common cause for refractory seizures. One of these types of histological features is frequently found in specimens of patients with temporal lobe epilepsy. MRI is able to show a clear pathology especially in FCD type 2. However, type 1 pathology is often unclearly seen, and thus having a normal MRI examination.¹⁹

Limitations of this study were not assessing myelin density, not using age stratification of the control group according to the sample, and not measuring dissemination in the white matter of other sites. Another limitation is the non-intact hippocampal preparation, either due to surgical techniques or tissue handling during histopathological examination. The lack of any other correlations between the MR and the histopathology measures could be due to some factors. A true correlation may exist and not have been detected, possibly because of the limited number of subjects with normal MR (10 patients). It could be also the registration between the MR region and the pathological region was inadequate.

CONCLUSION

MTR had fairly good sensitivity and EEG concordance, but low specificity so the result may be indicative for diagnostic accuracy to determine MTLE lateralization with normal MRI.

REFERENCES

1. Fisher RS, van Emde Boas W, Blume W, Elger C, Genton P, Lee P, et al. Epileptic Seizures and Epilepsy: Definitions Proposed by the International League Against Epilepsy (ILAE) and the International Bureau for Epilepsy (IBE). *Epilepsia* 2005; 46 (Issue 4): 467-607. Doi: <https://doi.org/10.1111/j.0013-9580.2005.66104.x>
2. Wiebe S, Blume W, Girvin JP, Eliasziw M. A Randomized, Controlled Trial of Surgery for Temporal-Lobe Epilepsy. *N Engl J Med* 2001; 345:311-318. DOI:10.1056/NEJM200108023450501
3. Muttaqin Z. Surgery for Temporal Lobe Epilepsy in Semarang, Indonesia: The First 56 Patients with Follow up Longer than 12 months. *Neurology Asia* 2006;11:31-36
4. Kuzniecky RI. Neuroimaging in Epilepsy. *Neurology* 2008;14(4):175-187
5. Salmenpera TM, Symm MR, Rugg-Gunn FJ, Boulby PA, Free SL, Barker GJ, et al. Evaluation of Quantitative Magnetic Resonance Imaging Contrast in MRI-Negative Refractory Focal Epilepsy. *Epilepsia* 2007;48(2):229-237
6. Van der Voorn JP, Powers JM, Kamphorst W, Martin JJ, Troost D, Spreuwenberg MD, et al. Correlating Quantitative MRI Imaging with Histopathology in X-linked Adrenoleukodystrophy. *Am J Neuroradiol.* 2011;32:481-489
7. Londono A, Castillo M, Lee YZ, Smith JK. Apparent Diffusion Coefficient Measurement in the Hippocampi in Patients with Temporal Lobe Seizures. *Am.J.Neuroradiol.* 2003;24:1582-1586
8. Toft PS, Sisodiya S, Barker GJ, Webb S, MacManus D, Fish D, et al. MR Magnetization Transfer Measurements in Temporal Lobe Epilepsy: A Preliminary Study. *AJNR*1995;16:1862-1863
9. Li LM, Narayanan S, Pike GB, Anderman F, Dubeau, Arnold DL. Magnetization Transfer Ratio Is Unable to Lateralize Epileptic Foci in Patients with Temporal Lobe Epilepsy. *Am J Neuroradiol.* 2000;21:1853-1856
10. Rugg-Gunn FJ, Eriksson SH, Boulby PA, Symms MR, Barker GJ, Duncan JS. Magnetization Transfer Imaging in Focal Epilepsy. *Neurology* 2003;60(10):1638-1645
11. Nave RD, Magaudda A, Michelucci R, Capizzi G, Calabro A, Guerrini L, et al. Whole Brain Histogram and Voxel based Analyses of Apparent Diffusion Coefficient and Magnetization Transfer Ratio in Celiac Disease, Epilepsy, and Cerebral Calcification Syndrome. *Am J Neuroradiol* 2007;28:479-485
12. Diniz PRB, Velasco TR, Salmon CEG, Sakamoto AC, Leitea JP, Santos AC. Extratemporal Damage in Temporal Lobe Epilepsy: Magnetization Transfer Adds Information to Volumetric MR Imaging. *AJNR* 2011; 32: 1857-1861
13. Errikson S.H., Free S.L., Thom M, Martinian L, Symms M.R., Salmenpera T.M. et al. Correlation of Quantitative MRI and Neuropathology in Epilepsy Surgical Resection Specimen- T2 Correlates with Neuronal Tissue in Gray Matter. *Neuroimage* 2007;37: 48-55
14. Lascola CD, Song AW, Haystead TA, Warner DS, Verleysen K, Freed TA, et al. Changes in Magnetization Transfer MRI Correlate With Spreading Depression-induced Astroglial Reactivity and Increased Protein Expression in Mice. *AJR.* 2004; 183:1791-1797
15. Fjær S, Lars B, Lundervold A, Myhr K M2, Pavlin T, Torkildsen Q, et al. Deep Gray Matter Demyelination Detected by Magnetization Transfer Ratio in the Cuprizone Model. *www.plosone.org* 2013;8 (12):1-10
16. Blumcke I, Thom M, Wiestler OD. Ammon's horn Sclerosis: A Maldevelopmental Disorder Associated with Temporal Lobe Epilepsy. *Brain Pathology* 2002;12(2): 199-211
17. Blumcke I, Hom M, Aronica E, Armstrong DD, Vinters H V, et al. The clinicopathologic spectrum of focal cortical dysplasias: A consensus classification proposed by an ad hoc Task Force of the ILAE Diagnostic Methods Commission. *Epilepsia* 2011; 52: 158-174
18. Hom M, Martinian L, Catarino C, Yogarajah M, Koepp MJ, et al. Bilateral reorganization of the dentate gyrus in hippocampal sclerosis: A postmortem study. *Neurology* 2009;73: 1033-1040.

Sensitivity Evaluation of Magnetization Transfer Ratio for Diagnosing Intractable Mesial Temporal Lobe Epilepsy with Normal MRI: Experience in Indonesia

ORIGINALITY REPORT

10%

SIMILARITY INDEX

8%

INTERNET SOURCES

8%

PUBLICATIONS

%

STUDENT PAPERS

PRIMARY SOURCES

1	www.ajnr.org Internet Source	2%
2	www.ncbi.nlm.nih.gov Internet Source	2%
3	www.ecmj.org.cn Internet Source	1%
4	www.jle.com Internet Source	1%
5	Reeves, C, M Tachrount, DL Thomas, Z Michalak, J Liu, M Ellis, B Diehl, A Miserocchi, A W McEvoy, S Eriksson, T Yousry, and M Thom. "Combined ex-vivo 9.4T MRI and quantitative histopathological study in normal and pathological neocortical resections in focal epilepsy : Cortical 9.4T MRI and neuropathology in epilepsy", Brain Pathology, 2015. Publication	1%

6	Ruth Helena Morais Bonini. "Magnetization transfer ratio as a predictor of malignancy in breast lesions: Preliminary results", <i>Magnetic Resonance in Medicine</i> , 05/2008 Publication	1%
7	math.bu.edu Internet Source	<1%
8	Eleonora Aronica. "Malformations of Cortical Development : Malformations", <i>Brain Pathology</i> , 05/2012 Publication	<1%
9	journals.sagepub.com Internet Source	<1%
10	"Wednesday July 5, 2006 15:00?17:00 Hall 3D Discussion Group Session Brain inflammation in temporal lobe epilepsy", <i>Epilepsia</i> , 12/2006 Publication	<1%
11	S.H. Eriksson, S.L. Free, M. Thom, L. Martinian et al. "Correlation of quantitative MRI and neuropathology in epilepsy surgical resection specimens—T2 correlates with neuronal tissue in gray matter", <i>NeuroImage</i> , 2007 Publication	<1%
12	www.science.gov Internet Source	<1%

13

Internet Source

<1%

14

openaccess.leidenuniv.nl

Internet Source

<1%

15

"Saturday Poster Session", Journal of Cardiovascular Magnetic Resonance, 2007

Publication

<1%

16

"Abstracts Presented at the Thirty–Fourth Annual International Neuropsychological Society Conference, February 1–4, 2006, Boston, Massachusetts, USA", Journal of the International Neuropsychological Society, 2006

Publication

<1%

17

Meneka K. Sidhu, Jason Stretton, Gavin P. Winston, Silvia Bonelli et al. "A functional magnetic resonance imaging study mapping the episodic memory encoding network in temporal lobe epilepsy", Brain, 2013

Publication

<1%

18

Thivard, L.. "Diffusion tensor imaging in medial temporal lobe epilepsy with hippocampal sclerosis", Neuroimage, 20051115

Publication

<1%

Exclude bibliography On

Sensitivity Evaluation of Magnetization Transfer Ratio for Diagnosing Intractable Mesial Temporal Lobe Epilepsy with Normal MRI: Experience in Indonesia

GRADEMARK REPORT

FINAL GRADE

/0

GENERAL COMMENTS

Instructor

PAGE 1

PAGE 2

PAGE 3

PAGE 4

PAGE 5
